

# Oral Cancer and Precancerous Lesions

Brad W. Neville, DDS; Terry A. Day, MD, FACS

**ABSTRACT** In the United States, cancers of the oral cavity and oropharynx represent approximately three percent of all malignancies in men and two percent of all malignancies in women. The American Cancer Society estimates that 28,900 new cases of oral cancer will be diagnosed in 2002, and nearly 7,400 people will die from this disease. Over 90 percent of these tumors are squamous cell carcinomas, which arise from the oral mucosal lining. In spite of the ready accessibility of the oral cavity to direct examination, these malignancies still are often not detected until a late stage, and the survival rate for oral cancer has remained essentially unchanged over the past three decades. The purpose of this article is to review the clinical features of oral cancer and premalignant oral lesions, with an emphasis on early detection. (*CA Cancer J Clin* 2002;52:195-215.)

**Dr. Neville** is Professor and Director, Division of Oral and Maxillofacial Pathology, Department of Stomatology, College of Dental Medicine, Medical University of South Carolina, Charleston, SC.

**Dr. Day** is Associate Professor and Director, Division of Head and Neck Oncologic Surgery, Department of Otolaryngology, Head and Neck Surgery, College of Medicine, Medical University of South Carolina, Charleston, SC.

This article is also available at [www.cancer.org](http://www.cancer.org).

## INTRODUCTION

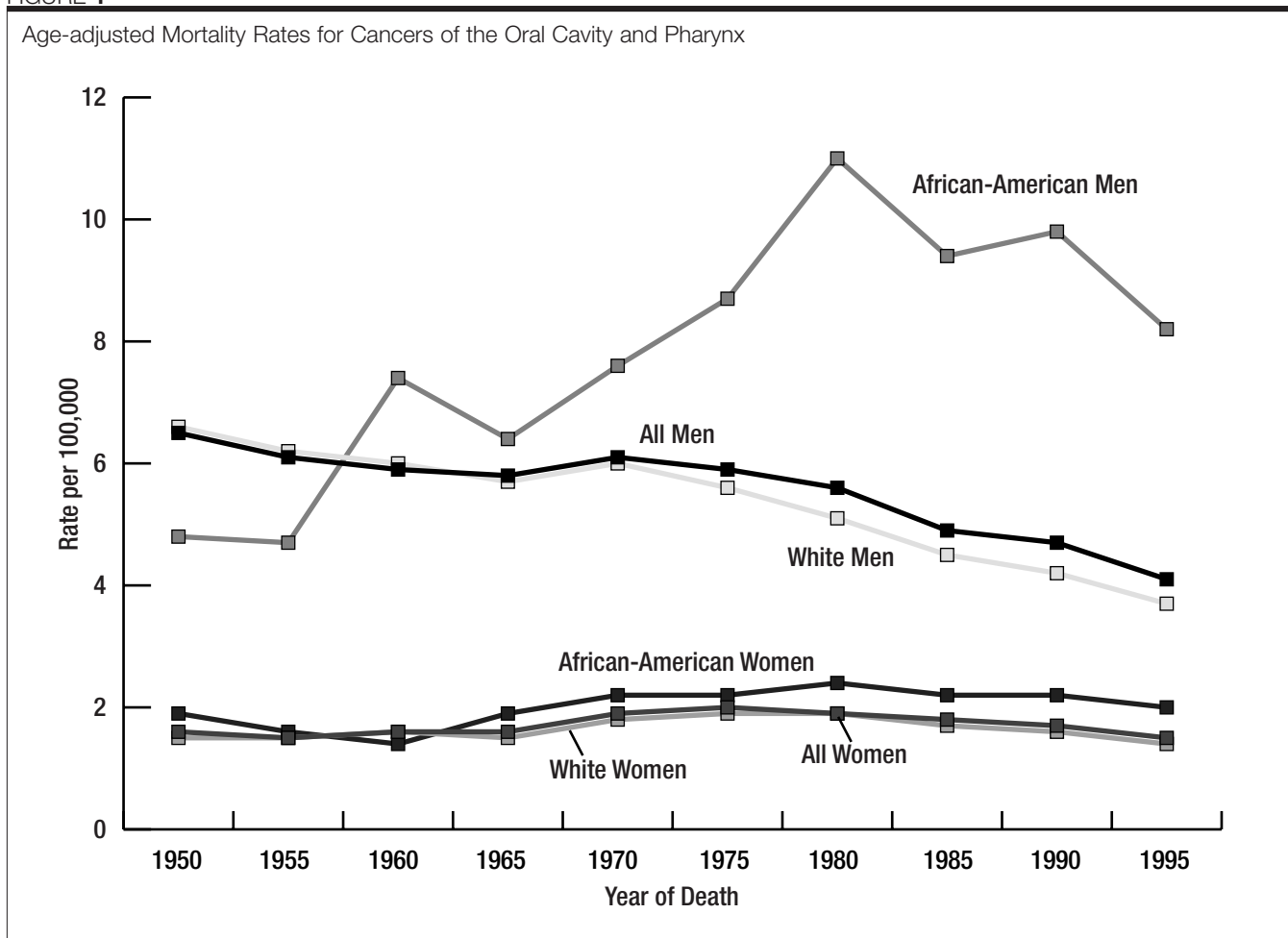
Cancers of the oral cavity and oropharynx represent approximately three percent of all malignancies in men and two percent of all malignancies in women in the United States. It is estimated that these tumors will account for 28,900 new cases and 7,400 deaths in 2002 in the United States.<sup>1</sup> Squamous cell carcinoma, which arises from the oral mucosal lining, accounts for over 90 percent of these tumors.<sup>2-4</sup> This article will review the epidemiology and clinical features of oral and oropharyngeal squamous cell carcinoma, with a special emphasis on the recognition of early cancer and premalignant oral lesions.

## EPIDEMIOLOGY

Oral cancer most commonly occurs in middle-aged and older individuals, although a disturbing number of these malignancies is also being documented in younger adults in recent years.<sup>5-7</sup> From an epidemiological and clinicopathological perspective, "oral cancer" can be divided into three categories: carcinomas of the oral cavity proper, carcinomas of the lip vermilion, and carcinomas arising in the oropharynx. Intraoral and oropharyngeal tumors are more common among men than women, with a male:female ratio of over 2:1.<sup>2,8-9</sup> However, the disparity in the male:female ratio has become less pronounced over the past half century, probably because women have been more equally exposing themselves to known oral carcinogens such as tobacco and alcohol.<sup>4,5</sup> The annual incidence of oral and

FIGURE 1

Age-adjusted Mortality Rates for Cancers of the Oral Cavity and Pharynx



Over the past 50 years, the mortality rate for oral/pharyngeal cancer has slightly improved in white men, whereas it has significantly worsened for African-American men.

pharyngeal cancer in African Americans (12.4 cases per 100,000 population) is higher than among whites (9.7 cases per 100,000); the highest incidence rate is among African-American males (20.5 cases per 100,000 population).<sup>3,9</sup>

In contrast to intraoral and oropharyngeal carcinomas, cancers of the lip vermilion are more akin epidemiologically to squamous cell carcinoma of the skin and occur primarily in white men.<sup>2</sup> These lip tumors are most strongly associated with chronic sun exposure, although sometimes they have been related to the site where cigarettes or pipestems have habitually

been held.<sup>10</sup> These malignancies are much more common in men, probably because men are more likely to have vocations and/or avocations that result in greater cumulative sun exposure. At one time, the lip was the most common site for oral cancer; however, the incidence of cancer in this location has decreased significantly over the past half century because fewer men hold outdoor occupations.<sup>2,4</sup>

Despite advances in surgery, radiation, and chemotherapy, the five-year survival rate for oral cancer has not improved significantly over

the past several decades and it remains at about 50 to 55 percent.<sup>3,9</sup> Unfortunately, African Americans have a significantly higher mortality rate when compared with whites (4.4 versus 2.4 per 100,000 population), partly because among African Americans, tumors are more often discovered at an advanced stage (Figure 1).<sup>3,9,11,12</sup> From 1985 to 1996, the five-year survival rate for carcinoma of the tongue in African-American men was 27 percent, compared with a 47 percent five-year survival rate among white men.<sup>3</sup> For floor of mouth cancers, the survival rate was 52 percent in whites, compared with only 33 percent among African Americans. When compared with intraoral carcinoma, the prognosis for lip cancer is quite good, with a five-year survival rate of 95 percent.<sup>2,3</sup>

#### RISK FACTORS

The strong association between cancers of the oral cavity and pharynx with tobacco use is well established. Epidemiological studies show that the risk of developing oral cancer is five to nine times greater for smokers than for nonsmokers, and this risk may increase to as much as 17 times greater for extremely heavy smokers of 80 or more cigarettes per day.<sup>2,13-17</sup> The percentage of oral cancer patients who smoke (approximately 80 percent) is two to three times greater than that of the general population. In addition, treated oral cancer patients who continue to smoke have a two to six times greater risk of developing a second malignancy of the upper aerodigestive tract than those who stop smoking.<sup>10,18</sup> Marijuana use is also considered to be a potential risk factor and may be partly responsible for the rise in oral cancers seen among young adults.<sup>3,7,19</sup> However, further epidemiological studies are necessary to confirm the purported association of marijuana and oral cancer in younger patients.

Snuff and chewing tobacco have also been associated with an increased risk for oral cancer.<sup>20</sup> In one study of women in the southern United States, chronic users of snuff were estimated to have a four times greater risk of developing oral cancer.<sup>21</sup> In addition, a significant number of oral cancers in smokeless tobacco users develop at the site of tobacco placement. However, the use of smokeless tobacco appears to be associated with a much lower cancer risk than that associated with smoked tobacco. The incidence of oral cancer in West Virginia is below the national average, even though this state has the highest consumption of chewing tobacco in the United States.<sup>22</sup> Recent studies from Scandinavia have suggested that the use of Swedish snuff (which is nonfermented and has lower nitrosamine levels) is not associated with an increased risk for oral cancer.<sup>17,23</sup>

Alcohol use has been identified as a major risk factor for cancers of the upper aerodigestive tract. In studies controlled for smoking, moderate-to-heavy drinkers have been shown to have a three to nine times greater risk of developing oral cancer.<sup>13,14,16,17</sup> One study from France showed that extremely heavy drinkers (greater than 100 grams of alcohol per day) had a 30 times greater risk of developing oral and oropharyngeal cancer (a typical serving of beer, wine, or liquor contains ten to 15 grams of alcohol).<sup>15</sup> Of even greater significance is the synergistic effect of alcohol and smoking; some subsets of patients who are both heavy smokers and heavy drinkers can have over one hundred times greater risk for developing a malignancy.<sup>15,16</sup>

In India and Southeast Asia, the chronic use of betel quid (*paan*) in the mouth has been strongly associated with an increased risk for oral cancer.<sup>24-26</sup> The quid typically consists of a betel leaf that is wrapped around a mixture of areca nut and slaked lime, usually with tobacco and sometimes with sweeteners and condiments. The slaked lime results in the

release of an alkaloid from the areca nut, which produces a feeling of euphoria and well-being in the user. Betel quid chewing often results in a progressive, scarring precancerous condition of the mouth known as oral submucous fibrosis. In India, one study showed a malignant transformation rate of 7.6 percent for oral submucous fibrosis.<sup>25</sup>

Recent evidence suggests that human papillomavirus (HPV) may be associated with some oral and oropharyngeal cancers.<sup>27-31</sup> HPV-16 has been detected in up to 22 percent of oral cancers, and HPV-18 has been found in up to 14 percent of cases.<sup>28</sup> Dietary factors, such as a low intake of fruits and vegetables, may also be related to an increased cancer risk.<sup>32,33</sup> As previously indicated, chronic actinic exposure is associated with the development of carcinomas of the lip vermilion.

A number of studies have suggested that oral lichen planus, especially the erosive form, may be associated with an increased cancer risk, although other investigators have questioned the strength of this association.<sup>34-36</sup> Iron deficiency anemia in combination with dysphagia and esophageal webs (known as Plummer-Vinson or Paterson-Kelly syndrome) is associated with an elevated risk for development of carcinoma of the oral cavity, oropharynx, and esophagus.<sup>37,38</sup> Immunosuppression appears to predispose some individuals to an increased risk for oral cancer. Carcinomas of the lip have been reported in a number of kidney transplant patients receiving immunosuppressive medications, and oral carcinomas have been documented in young AIDS patients.<sup>39-42</sup>

---

#### EARLY DIAGNOSIS

Despite the great strides that have been

made in recent decades to improve the prognosis for a number of cancers throughout the body, the prognosis for oral cancer has not experienced a similar improvement.<sup>3,8,11</sup>

Because five-year survival is directly related to stage at diagnosis, prevention and early detection efforts have the potential not only for decreasing the incidence, but also for improving the survival of those who develop this disease. Early diagnosis depends upon an astute clinician or patient who may identify a suspicious lesion or symptom while it is still at an early stage. However, it is apparent that many clinicians, including dentists and physicians, may not be knowledgeable about the risk factors, diagnosis, and early detection of these cancers and/or are not performing routine oral cancer examinations.<sup>43-49</sup>

The Centers for Disease Control and Prevention's 1998 National Health Interview Survey (NHIS) Adult Prevention Supplement included questions regarding examinations for oral cancer. Participants were asked "Have you ever had a test for oral cancer in which the doctor or dentist pulls on your tongue, sometimes with gauze wrapped around it, and feels under the tongue and inside the cheeks?" Only 16 percent of respondents reported that they ever had such an exam. This reported cumulative prevalence of oral cancer exams was higher in whites (18 percent) than in African Americans (10 percent), American Indians/Alaska Natives (8 percent), or Asian/Pacific Islanders (11 percent). Former smokers (21 percent) were more likely than current smokers (13 percent) or people who had never smoked (16 percent) to recall having ever had this examination. Among all individuals who reported having had an oral cancer exam, 70 percent reported that their last exam was within the past year.\*

---

\*Vilma Cokkinides, PhD, (personal communication, May 2002), based on an analysis of the NHIS 1998 Adult Prevention Supplement Public Use Data Release accessed at [www.cdc.gov/nchs/nhis.htm](http://www.cdc.gov/nchs/nhis.htm).

Early oral cancers and precancerous lesions are often subtle and asymptomatic. Therefore, it is important for the clinician to maintain a high index of suspicion, especially if risk factors such as tobacco use or alcohol abuse are present. Invasive oral squamous cell carcinoma is often preceded by the presence of clinically identifiable premalignant changes of the oral mucosa. These lesions often present as either white or red patches, known as leukoplakia and erythroplakia. As the cancer develops, the patient may notice the presence of a nonhealing ulcer. Later-stage symptoms include bleeding, loosening of teeth, difficulty wearing dentures, dysphagia, dysarthria, odynophagia, and development of a neck mass.

The American Cancer Society recommends a cancer-related check-up annually for all individuals aged 40 and older, and every three years for those between the ages of 20 and 39, which “should include health counseling and, depending on a person’s age, might include examinations for cancers of the thyroid, oral cavity, skin, lymph nodes, testes, and ovaries.”<sup>50</sup> According to the US Preventive Health Services Task Force (USPHSTF), “there is insufficient evidence to recommend for or against routine screening of asymptomatic persons for oral cancer by primary care clinicians ... clinicians may wish to include an examination for cancerous and precancerous lesions of the oral cavity in the periodic health examination of persons who chew or smoke tobacco (or did so previously), older persons who drink regularly, and anyone with suspicious symptoms or lesions detected through self-examination. ... Appropriate counseling should be offered to those persons who smoke cigarettes, pipes, or cigars, those who use chewing tobacco or snuff, and those who demonstrate evidence of alcohol abuse.”<sup>51</sup> The USPHSTF document also notes that “...both the National Cancer Institute and the National Institute of Dental Research (subsequently renamed the National Institute

of Dental and Craniofacial Research) support efforts to promote the early detection of oral cancers during routine dental examinations.”

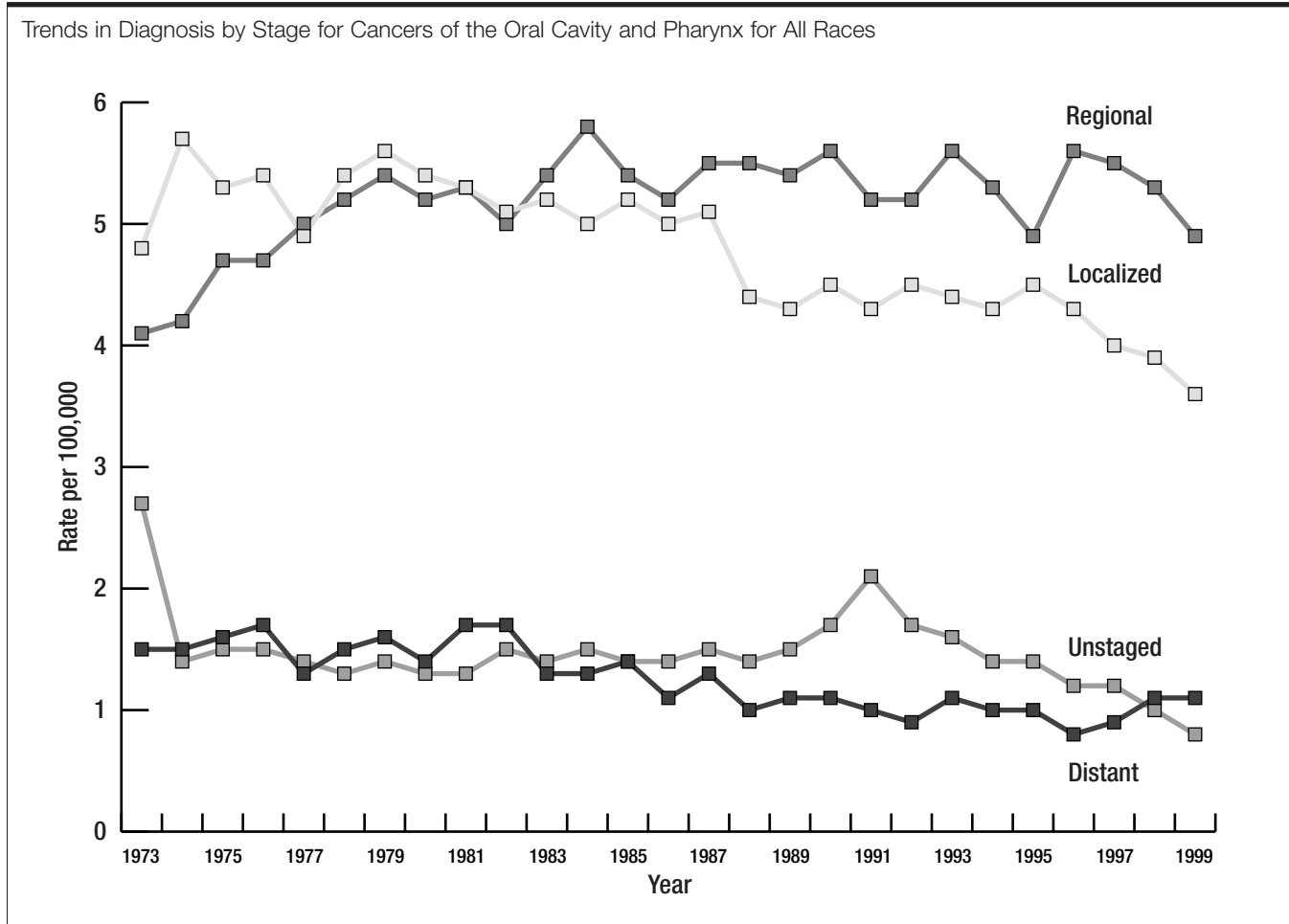
Clearly, the low prevalence of oral cancer screening reported in the NHIS indicates that most clinicians are not following ACS recommendations, and are not even following the USPHSTF suggestion for examinations in tobacco users and other high-risk individuals.

Unfortunately, there has been little improvement in the early detection of oral cancer because many patients do not present for diagnosis and treatment until they have Stage III or Stage IV disease (Figure 2). Therefore, in order to improve oral cancer survival, public education efforts are also necessary to encourage patients to avoid high-risk behaviors and to ask their health care providers about regular oral cancer screening examinations.

#### LEUKOPLAKIA

The term *leukoplakia* was first used by Schwimmer in 1877 to describe a white lesion of the tongue, which probably represented a syphilitic glossitis.<sup>52</sup> The definition of leukoplakia has often been confusing and controversial—so much so, that some clinicians now avoid using this term in their lexicon. As defined by the World Health Organization, leukoplakia is “a white patch or plaque that cannot be characterized clinically or pathologically as any other disease.”<sup>53</sup> As such, leukoplakia should be used only as a clinical term; it has no specific histopathological connotation and should never be used as a microscopic diagnosis.<sup>54</sup> In the evaluation of the patient, leukoplakia is a clinical diagnosis of exclusion. If an oral white patch can be diagnosed as some other condition (e.g., candidiasis, lichen planus, leukoedema, etc.), then the lesion should not be considered to be an example of leukoplakia. Sometimes a white

FIGURE 2



Over the past 25 years, no significant improvement has been made in the early diagnosis of oral/pharyngeal cancer.

patch is initially believed to represent leukoplakia, but the biopsy reveals another specific diagnosis. In such cases, the lesion should no longer be categorized as a leukoplakia.

The usage of the term leukoplakia continues to undergo refinement.<sup>55</sup> Frequently, oral white patches are seen secondary to identifiable local irritation. For example, thickened hyperkeratotic changes are frequently found on the edentulous areas of the alveolar ridges, especially in patients who do not wear an overlying dental prosthesis

(Figure 3). Because these exposed edentulous sites receive more irritation during mastication, there is a natural tendency for the epithelium to become more hyperkeratotic as a protective phenomenon, similar to a callus developing on one's hand. Because such "ridge keratoses" rarely ever show any dysplastic changes or transform into carcinoma, most experts prefer placing them into a separate category ("frictional keratoses"), rather than considering them to be leukoplakias.<sup>2,55</sup> Likewise, hyperkeratotic changes that develop secondary to chronic cheek chewing

(“morsicatio buccarum”) or tongue chewing (“morsicatio linguarum”) should not be classified as leukoplakia; such lesions are not premalignant and they are readily reversible if the irritation is avoided.

Two specific tobacco-related lesions of the oral mucosa, nicotine stomatitis and tobacco pouch keratosis, have often been included under the broad umbrella of leukoplakia. However, because these lesions have a specific known cause and prognosis, we prefer to classify them separately from leukoplakia.

Leukoplakia is seen most frequently in middle-aged and older men, with an increasing prevalence with age.<sup>2,56</sup> Fewer than one percent of men below the age of 30 have leukoplakia, but the prevalence increases to an alarming eight percent in men over the age of 70.<sup>56</sup> The prevalence in women past the age of 70 is approximately two percent. The most common sites are the buccal mucosa, alveolar mucosa, and lower lip; however, lesions in the floor of mouth, lateral tongue, and lower lip are most likely to show dysplastic or malignant changes.<sup>57</sup>

Early or thin leukoplakia appears as a slightly elevated grayish-white plaque that may be either well defined or may gradually blend into the surrounding normal mucosa (Figure 4).<sup>2,58</sup> As the lesion progresses, it becomes thicker and whiter, sometimes developing a leathery appearance with surface fissures (homogeneous or thick leukoplakia) (Figure 5). Some leukoplakias develop surface irregularities and are referred to as granular or nodular leukoplakias (Figure 6). Other lesions develop a papillary surface and are known as verrucous or verruciform leukoplakia (Figure 7).

One uncommon variant, known as proliferative verrucous leukoplakia (PVL), is characterized by widespread, multifocal sites of involvement, often in patients without known risk factors.<sup>59-63</sup> The condition begins with conventional flat white patches that, over time,

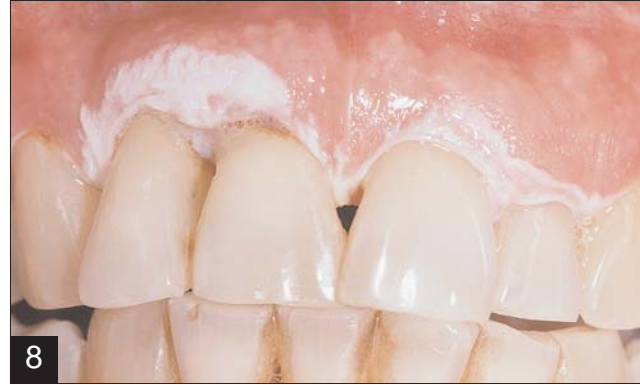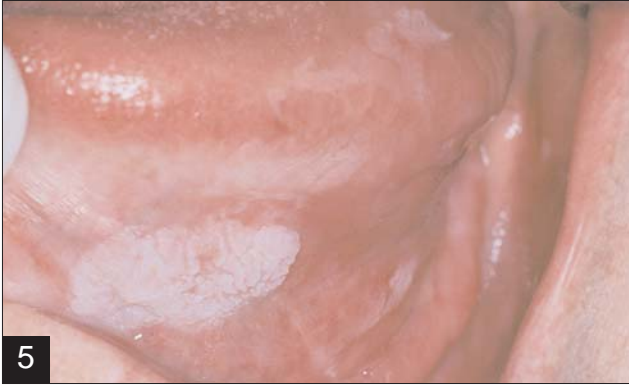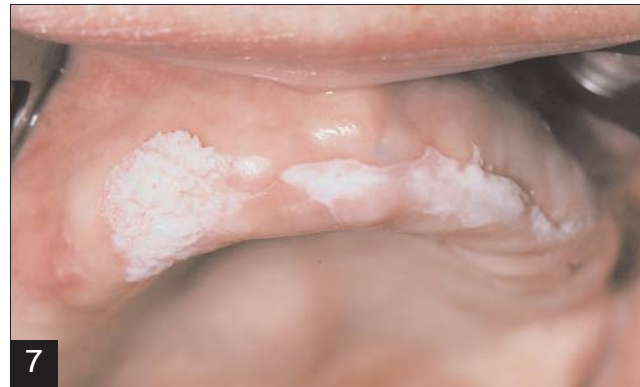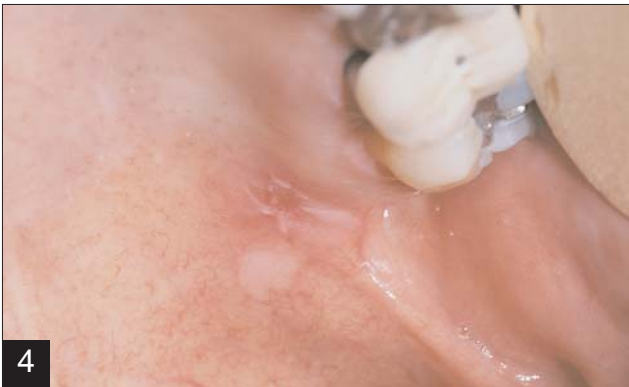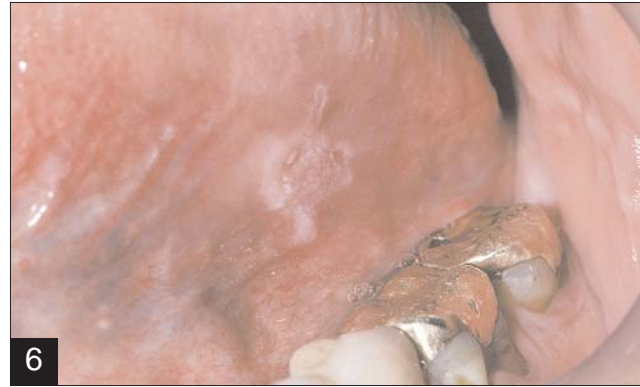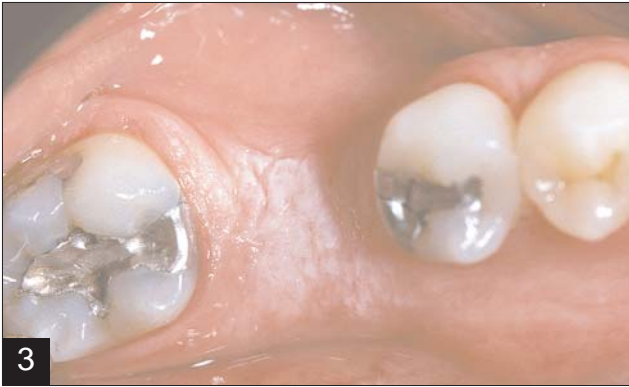TABLE 1

Histopathological Nature of Leukoplakia by Site (3,360 Biopsy Specimens) <sup>57</sup>		
Site	% of Leukoplakias at this site	% of Leukoplakias at this site that showed dysplasia or carcinoma
Lips	10.3	24.0
Maxillary mucosa and sulcus	10.7	14.8
Mandibular mucosa and sulcus	25.2	14.6
Palate	10.7	18.8
Buccal mucosa	21.9	16.5
Tongue	6.8	24.2
Floor of mouth	8.6	42.9
Retromolar	5.9	11.7
<b>Total</b>	<b>100.0</b>	19.9 (average for all sites)

Source: Waldron CA, Shafer WG. Leukoplakia revisited: A clinicopathological study of 3,256 oral leukoplakias. *Cancer* 1975;36:1386-1392.

tend to become much thicker and papillary in nature (Figure 8). This papillary proliferation may progress to the point where the lesion can be categorized microscopically as a verrucous carcinoma. However, in spite of treatment, the lesions have a high recurrence rate and often eventually transform into more aggressive squamous cell carcinoma.

In recent years, a number of oral white patches have been identified that appear to be related to the use of toothpastes or mouth rinses containing the herbal extract, sanguinaria.<sup>64-66</sup> Such lesions most frequently have been identified on the maxillary alveolar mucosa and buccal vestibule, although some patients have developed lesions on the mandibular alveolar mucosa. Microscopically, these lesions usually show hyperkeratosis and epithelial atrophy, sometimes in association with true dysplasia, although the potential for the development of cancer is uncertain.



**Figure 3 Frictional ridge keratosis.** This rough, white change of the edentulous area of the alveolar ridge represents a frictional hyperkeratosis because this area now receives more irritation during mastication. This should not be mistaken for true leukoplakia, and biopsy is not indicated.

**Figure 4 Early or thin leukoplakia.** This subtle white patch on the lateral soft palate showed severe epithelial dysplasia on biopsy.

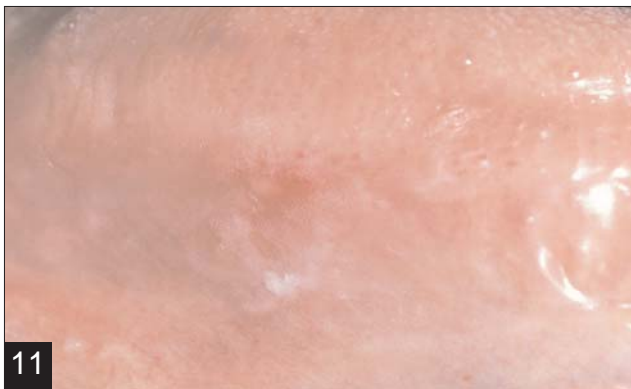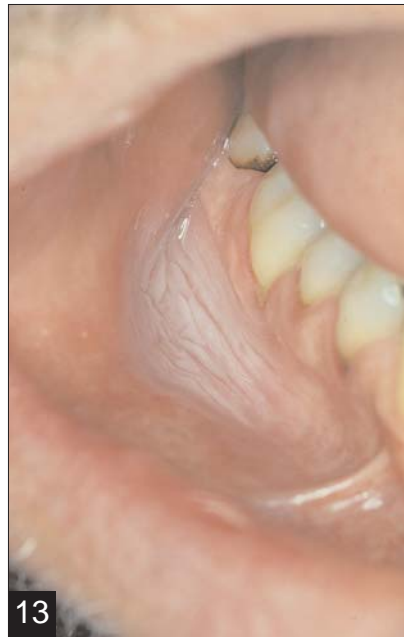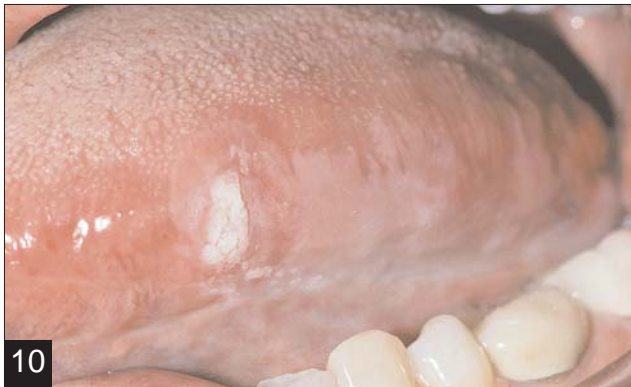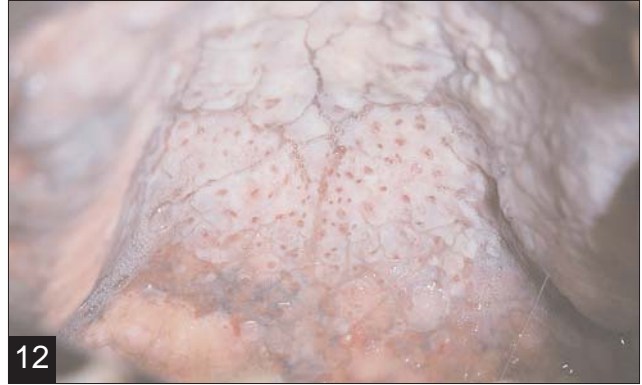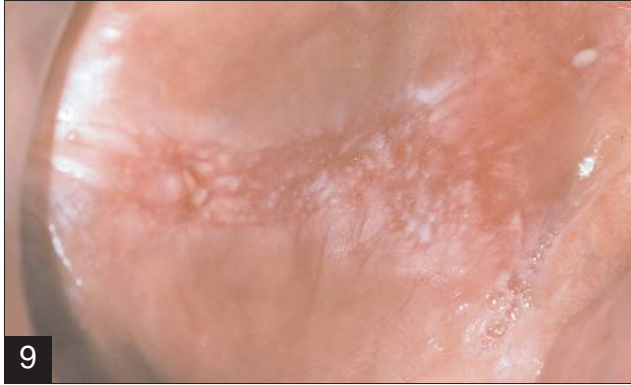**Figure 5 Thick leukoplakia.** This thick white lesion on the lateral/ventral tongue showed moderate epithelial dysplasia. Thinner areas of leukoplakia are visible on the more posterior aspects of the lateral tongue and in the floor of mouth.

**Figure 6 Granular leukoplakia.** A small leukoplakic lesion with a rough, granular surface on the posterior lateral border of the tongue. The biopsy revealed early invasive squamous cell carcinoma. Such a lesion would be easily missed during an oral examination unless the tongue is pulled out and to the side to allow visualization of this high-risk site. (Courtesy of Neville BW, Damm DD, Allen CM, et al. *Oral & Maxillofacial Pathology*, ed 2, Philadelphia, WB Saunders, 2002.)

**Figure 7 Verruciform leukoplakia.** The papillary component of this lesion on the left side of the picture (patient's right) showed well-differentiated squamous cell carcinoma.

**Figure 8 Proliferative verrucous leukoplakia.** This middle-aged gentleman has had a several year history of these recurring, spreading hyperkeratotic lesions that involve both the buccal and lingual gingiva. Multiple biopsies have ranged from simple hyperkeratosis to moderate epithelial dysplasia.





**Figure 9 Speckled leukoplakia.** This mixed white and red lesion of the buccal mucosa showed moderate epithelial dysplasia.

**Figure 10 Leukoplakia.** A diffuse leukoplakia of the left lateral border of the tongue. A biopsy of the thick, rough zone at the anterior aspect of the lesion showed early invasive squamous cell carcinoma.

**Figure 11 Erythroplakia.** This small, subtle red lesion on the right lateral border of the tongue showed carcinoma in situ on biopsy. Adjacent slight leukoplakic changes are also evident (erythro-leukoplakia). (Courtesy of Neville BW, Damm DD, Allen CM, et al. *Oral & Maxillofacial Pathology*, ed 2, Philadelphia, WB Saunders, 2002.)

**Figure 12 Nicotine stomatitis.** Rough, white, fissured appearance of the hard and soft palate in a heavy pipe smoker. The red, punctate areas represent the inflamed openings of the minor salivary gland ducts.

**Figure 13 Tobacco pouch keratosis.** A white, wrinkled change of the mucosa in the mandibular buccal vestibule secondary to the use of chewing tobacco.

TABLE 2

Malignant Transformation of Oral Leukoplakia (Europe and United States)				
Source	Country	Year	# of Patients	% of Patients with Malignant Transformation
Einhorn and Wersäll <sup>71</sup>	Sweden	1967	782	4.0
Silverman <sup>70</sup>	United States	1968	117	6.0
Pindborg et al. <sup>67</sup>	Denmark	1968	248	4.4
Kramer <sup>74</sup>	England	1969	187	4.8
Roed-Petersen <sup>75</sup>	Denmark	1971	331	3.6
Bánóczy <sup>72</sup>	Hungary	1977	670	6.0
Silverman et al. <sup>76</sup>	United States	1984	247	17.5
Lind <sup>77</sup>	Norway	1987	157	8.9
Bouquot and Gorlin <sup>56</sup>	United States	1988	463	10.3

Because sanguinaria-associated keratoses can be extensive or multifocal, sometimes they are misinterpreted as early proliferative verrucous leukoplakia.

Some leukoplakias occur in combination with adjacent red patches or erythroplakia. If the red and white areas are intermixed, the lesion is called a speckled leukoplakia or speckled erythroplakia (Figure 9).

The frequency of dysplastic or malignant alterations in oral leukoplakia has ranged from 15.6 to 39.2 percent in several studies.<sup>54,57,67-69</sup> In one large, well known retrospective study that looked at approximately 3,300 biopsies of oral white lesions, Waldron and Shafer determined that 19.9 percent of leukoplakias showed some degree of epithelial dysplasia (Table 1).<sup>57</sup> In this group, 3.1 percent were unsuspected squamous cell carcinoma, 4.6 percent showed severe dysplasia or carcinoma in situ, and 12.2 percent showed mild-to-moderate epithelial dysplasia. Differences in the frequency of dysplastic changes in leukoplakia studies may reflect selection bias or differences in the clinical definition of oral leukoplakia. If white lesions such as frictional ridge keratoses and nicotine

stomatitis are not included as examples of clinical leukoplakia, the percentage of cases showing dysplastic changes will be higher.

The location of oral leukoplakia has a significant correlation with the frequency of finding dysplastic or malignant changes at biopsy. In the study by Waldron and Shafer, the floor of mouth was the highest-risk site, with 42.9 percent of leukoplakias showing some degree of epithelial dysplasia, carcinoma in situ, or unsuspected invasive squamous cell carcinoma.<sup>57</sup> The tongue and lip were also identified as high-risk sites, with dysplasia or carcinoma present in 24.2 percent and 24.0 percent of these cases, respectively.

The clinical appearance of leukoplakia may also indicate some correlation with the likelihood that the lesion will show dysplastic or malignant features. In general, the thicker the leukoplakia, the greater the chance of finding dysplastic changes; therefore, a verrucous leukoplakia is more likely to show dysplasia than is a thick homogeneous leukoplakia, which, in turn, is more likely to show dysplasia than is a thin leukoplakia (Figure 10).<sup>58</sup> Leukoplakias with an intermixed

red component (speckled leukoplakia or mixed leukoplakia/erythroplakia) are at greatest risk for showing dysplasia or carcinoma. Pindborg and associates found 14 percent of speckled leukoplakias to show carcinoma, whereas another 51 percent showed epithelial dysplasia.<sup>67</sup> However, all leukoplakias should be viewed with suspicion because even small, subtle lesions can manifest significant dysplasia or unsuspected carcinoma.<sup>57,70</sup> Therefore, directed conventional biopsy is recommended for any true oral leukoplakia.

In addition to a small percentage of leukoplakias that will show invasive carcinoma when they are first sampled for biopsy, it is also recognized that currently non-carcinomatous leukoplakias are at risk for future malignant transformation. Several clinical studies have been conducted in Europe and the United States to assess the potential for malignant transformation of oral leukoplakia (Table 2).<sup>58,70-77</sup> Most of the earlier studies showed a risk of malignant transformation in the range of 3.6 to 6.0 percent. However, several of the more recent studies have shown more alarming malignant transformation rates ranging from 8.9 to 17.5 percent.<sup>58,76,77</sup> Although the reason for these results is unclear, it may be due to a more restrictive definition of what is considered clinical leukoplakia and further underscores the seriousness of "true leukoplakia." The study by Silverman and colleagues showed an overall malignant transformation of 17.5 percent.<sup>76</sup> In this study, only 6.5 percent of homogeneous leukoplakias underwent malignant change; however, 23.4 percent of speckled leukoplakias and 36.4 percent of leukoplakias with microscopic evidence of dysplastic changes transformed into cancer.

When compared with "conventional leukoplakia," proliferative verrucous leukoplakia is a particularly high-risk condition. In a follow-up study of 54 cases of proliferative verrucous leukoplakia, Silverman and Gorsky

found that 70.3 percent of the patients subsequently developed squamous cell carcinoma.<sup>62</sup>

Although leukoplakia is more common in men than women, several studies have shown that women with leukoplakia have a higher risk of developing oral carcinoma.<sup>70,72,75</sup> Another disturbing finding is that leukoplakias in nonsmokers are more likely to undergo malignant transformation than leukoplakias in patients who do smoke.<sup>71,72,75,76</sup> This should not be interpreted to detract from the well-established role of tobacco in oral carcinogenesis, but may indicate that nonsmokers who develop leukoplakia do so as a result of other more potent carcinogenic factors.

#### ERYTHROPLAKIA

The term *erythroplasia* was originally used by Queyrat to describe a red, precancerous lesion of the penis.<sup>78</sup> The term *erythroplakia* is used for a clinically and histopathologically similar process that occurs on the oral mucosa. Similar to the definition for leukoplakia, erythroplakia is a clinical term that refers to a red patch that cannot be defined clinically or pathologically as any other condition.<sup>53</sup> This definition excludes inflammatory conditions that may result in a red clinical appearance.

Oral erythroplakia occurs most frequently in older men and appears as a red macule or plaque with a soft, velvety texture (Figure 11).<sup>2</sup> The floor of mouth, lateral tongue, retromolar pad, and soft palate are the most common sites of involvement. Often the lesion is well demarcated, but some examples may gradually blend into the surrounding mucosa. Some lesions may be intermixed with white areas (erythroleukoplakia). Erythroplakia is often asymptomatic, although some patients may complain of a sore, burning sensation.

Although erythroplakia is not nearly as common as leukoplakia, it is much more likely

to show dysplasia or carcinoma. In a sister study to their large series of leukoplakia cases, Shafer and Waldron also analyzed their biopsy experience with 65 cases of erythroplakia.<sup>79</sup> All erythroplakia cases showed some degree of epithelial dysplasia; 51 percent showed invasive squamous cell carcinoma, 40 percent were carcinoma in situ or severe epithelial dysplasia, and the remaining 9 percent demonstrated mild-to-moderate dysplasia. Therefore, true clinical erythroplakia is a much more worrisome lesion than leukoplakia.<sup>80</sup> Likewise, in a mixed erythroleukoplakia, the red component is more likely to demonstrate dysplastic changes than is the white component; when selecting an appropriate biopsy site in a mixed lesion, the clinician should make sure that the specimen includes the red component.

#### NICOTINE STOMATITIS

Nicotine stomatitis is a thickened, hyperkeratotic alteration of the palatal mucosa that is most frequently related to pipe smoking, but milder examples can also develop secondary to cigar smoking or, rarely, from cigarette smoking.<sup>2,53</sup> The palatal mucosa becomes thickened and hyperkeratotic, sometimes developing a fissured surface (Figure 12). The surface often develops papular elevations with red centers, which represent the inflamed openings of the minor salivary gland ducts.

The term nicotine stomatitis is actually a misnomer because it isn't the nicotine that causes the changes; the changes are caused by the intense heat generated from the smoking. Nicotine stomatitis is seen more often in pipe smokers because of the great amount of heat that is generated from the pipestem. (Similar lesions have even been reported in patients who drink extremely hot beverages.)<sup>81</sup> Although nicotine stomatitis is a tobacco-related pathosis, it is not considered to be

pre-malignant and it is readily reversible with discontinuation of the tobacco habit.

However, in some Southeast Asian and South American countries, individuals practice a habit known as reverse smoking in which the lit end of the cigarette or cigar is placed in the mouth. This habit creates a more severe heat-related alteration of the palatal mucosa known as *reverse smoker's palate*, which has been associated with a significant risk of malignant transformation.<sup>10,82,83</sup>

#### TOBACCO POUCH KERATOSIS

Another specific tobacco-related oral mucosal alteration occurs in association with smokeless tobacco use, either from snuff or chewing tobacco.<sup>2,84-87</sup> Such lesions typically occur in the buccal or labial vestibule where the tobacco is held, but they can also extend onto the adjacent gingiva and buccal mucosa. Early lesions may show slight wrinkling that disappears when the tissues are stretched. Other lesions may appear as hyperkeratotic, granular patches. Advanced lesions exhibit greatly thickened zones of grayish white mucosa with well-developed folds and fissures (Figure 13). The degree of clinical alteration depends on the type and quantity of tobacco, the duration of tobacco usage, and host susceptibility.

Tobacco pouch keratoses can occur at any age, even in children and adolescents. In Western cultures, these lesions currently are seen most frequently in young men and men older than 65 years of age; such lesions are less common among middle-aged men because the habit of using smokeless tobacco has not been as popular in this generation.<sup>2</sup> In some rural Southern populations, smokeless tobacco keratoses are seen with some degree of frequency in older women, who may have started their snuff-dipping habit in early childhood.<sup>84</sup> Overall, it is estimated that 15

percent of chewing tobacco users and 60 percent of snuff users will develop clinical lesions, if mild examples are included.<sup>2</sup>

Microscopically, smokeless tobacco keratoses show hyperkeratosis and acanthosis of the mucosal epithelium. True epithelial dysplasia is uncommon; when dysplasia is found, it is usually mild in degree.<sup>84</sup> However, significant dysplasia or squamous cell carcinoma occasionally may be discovered.

Most tobacco pouch keratoses are readily reversible within two to six weeks after cessation of the tobacco habit.<sup>88</sup> If the lesion does not resolve after the habit is stopped, then an incisional biopsy of the area should be performed and the patient managed accordingly. Some clinicians also recommend biopsy for lesions in patients who will not discontinue their tobacco habit.

#### SQUAMOUS CELL CARCINOMA

Early squamous cell carcinoma often presents as a white patch (leukoplakia), red patch (erythroplakia), or a mixed red and white lesion (erythroleukoplakia). With time, superficial ulceration of the mucosal surface may develop (Figure 14). As the lesion grows, it may become an exophytic mass with a fungating or papillary surface (Figure 15); other tumors have an endophytic growth pattern that is characterized by a depressed, ulcerated surface with a raised, rolled border (Figure 16).<sup>2,89</sup> Pain is not a reliable indicator as to whether a particular lesion may be malignant; larger, advanced carcinomas will often be painful, but many early oral cancers will be totally asymptomatic or may be associated with only minor discomfort.

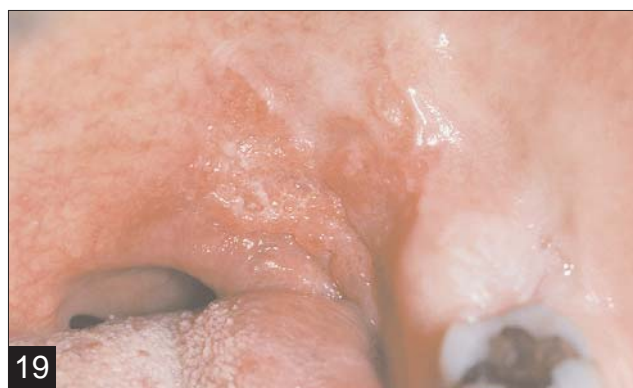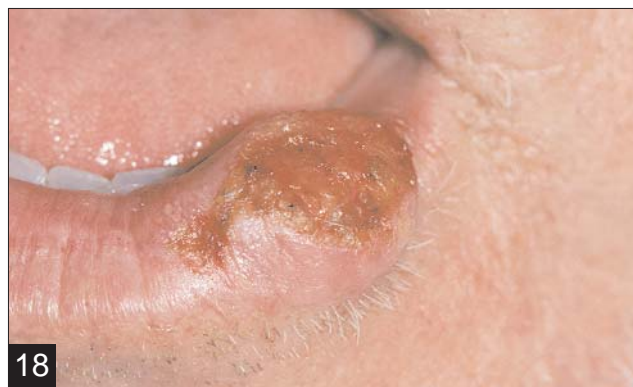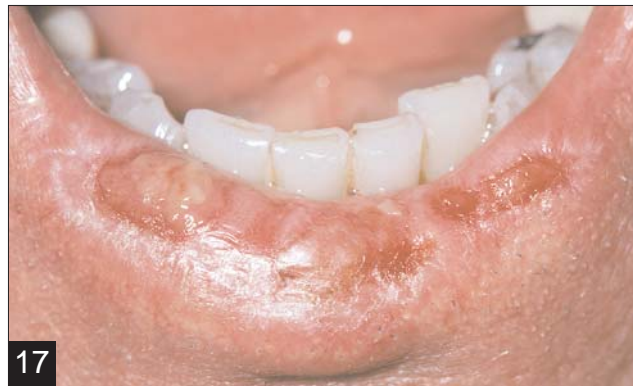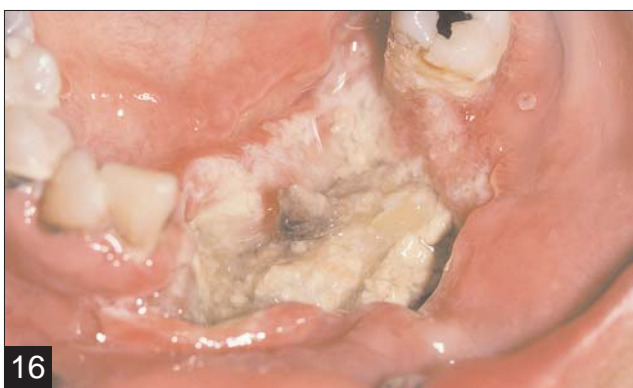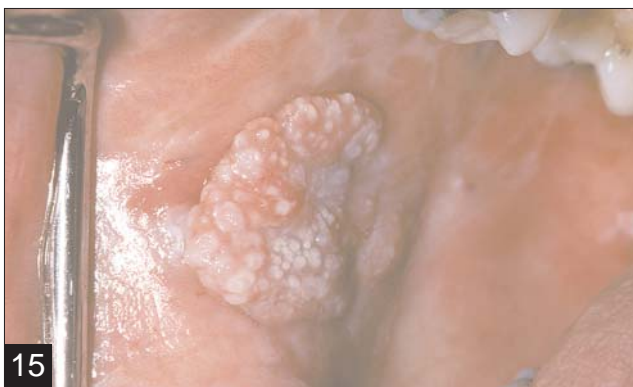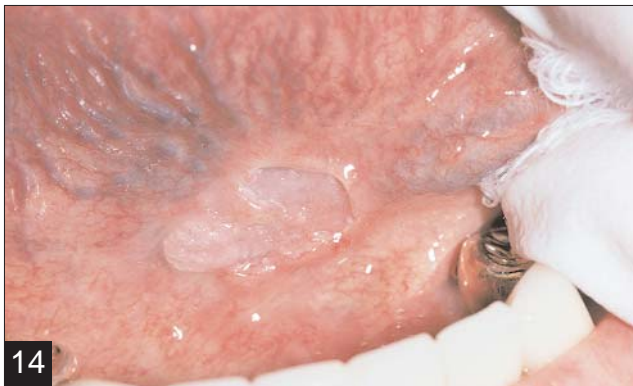The most common site for intraoral carcinoma is the tongue, which accounts for around 40 percent of all cases in the oral cavity proper. These tumors most frequently occur on the posterior lateral border and ventral surfaces

of the tongue. The floor of the mouth is the second most common intraoral location. Less-common sites include the gingiva, buccal mucosa, labial mucosa, and hard palate.<sup>2,4</sup>

The lateral tongue and floor of mouth (with extension back to the lateral soft palate and tonsillar area) combine to form a horseshoe-shaped region of the oral mucosa, which is at greatest risk for cancer development. There are two major factors that may explain why this region is at high risk: first, any carcinogens will mix with saliva, pool in the bottom of the mouth, and constantly bathe these sites; secondly, these regions of the mouth are covered by a thinner, nonkeratinized mucosa, which provides less protection against carcinogens.<sup>14</sup>

It is important for the clinician to be aware of this high-risk region when examining the oral cavity. During an examination, if a tongue blade or other instrument is used simply to depress the tongue in order to see the rest of the mouth, then the two most common sites for intraoral cancer will be hidden. It is recommended that a cotton gauze be used to grasp the tip of the tongue, allowing it to be pulled upward and to each side so that the lateral tongue and oral floor can be adequately seen.<sup>90</sup>

In addition to the oral cavity proper, squamous cell carcinomas also often develop on the lip vermilion and the oropharynx. Vermilion carcinomas show a striking predilection for the lower lip, and usually occur in light-skinned individuals with a long history of actinic damage. The lesion usually arises in an actinic cheilosis, a premalignant condition that is akin to actinic keratosis of the skin. Actinic cheilosis is characterized by atrophy of the vermilion border, which may develop dry, scaly changes. As the condition progresses, ulcerated sites may appear which partially heal, only to recur at a later date (Figure 17). (The patient often mistakes these recurring ulcerated lesions for "fever blisters.") The evolving cancer slowly becomes a crusted, nontender, indurated



**Figure 14 Squamous cell carcinoma.** Ulcerated lesion of the ventral tongue/floor of mouth.

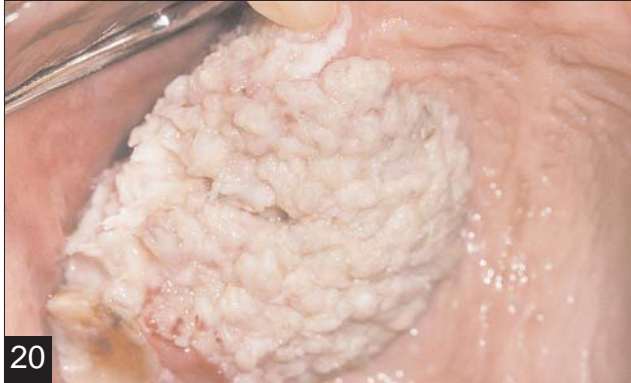**Figure 15 Squamous cell carcinoma.** Exophytic, papillary mass of the buccal mucosa.

**Figure 16 Squamous cell carcinoma.** Deeply invasive and crater-like ulcer of the anterior floor of mouth and alveolar ridge. The lesion had eroded into the underlying mandible.

**Figure 17 Actinic cheilosis.** Atrophic and ulcerated changes of the lower lip vermilion. Biopsy revealed early invasive squamous cell carcinoma.

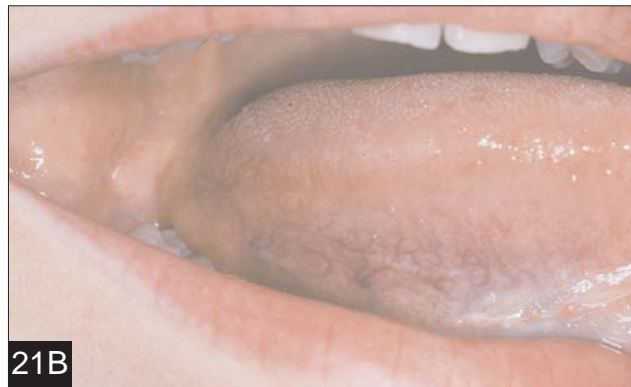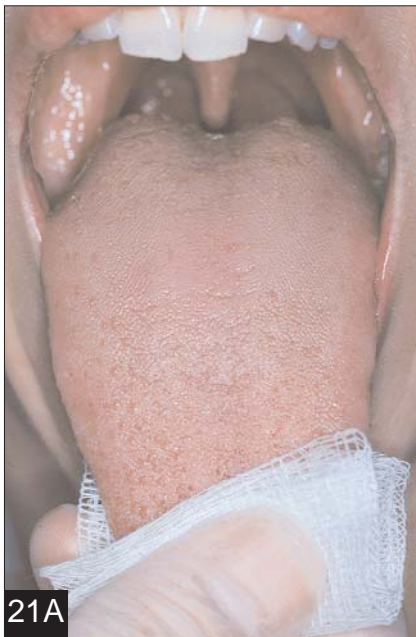**Figure 18 Squamous cell carcinoma.** Crusted, ulcerated mass of the lower lip vermilion.

**Figure 19 Squamous cell carcinoma.** Red, granular lesion of the left lateral soft palate and tonsillar region.



**Figure 20 Verrucous carcinoma.** White, exophytic, warty mass of the maxillary alveolar ridge. (Courtesy of Neville BW, Damm DD, Allen CM, et al. *Oral & Maxillofacial Pathology*, ed 2, Philadelphia, WB Saunders, 2002.)

**Figure 21 Examination of the oral cavity.** The tip of the tongue should be grasped with a piece of gauze (A) and pulled out to each side (B) to allow visualization of the posterior lateral borders and ventral surface of the tongue. This is the most common site for intraoral cancer.



ulcer or mass (Figure 18).<sup>2,89</sup>

Oropharyngeal carcinomas have a clinical appearance that is similar to cancers found in the oral cavity proper (Figure 19). Such tumors often arise on the lateral soft palate and tonsillar region, but also may originate from the base of the tongue. Unfortunately, such tumors are typically larger and more advanced at the time of discovery than are more anterior cancers of the oral cavity.<sup>2,3</sup> Presenting symptoms often include difficulty in swallowing (dysphagia), pain during swallowing (odynophagia), and pain referred to the ear (otalgia).

#### VERRUCOUS CARCINOMA

Verrucous carcinoma is a low-grade variant of oral squamous cell carcinoma and comprises approximately three percent of all primary invasive carcinomas of the oral mucosa.<sup>91</sup> It is often associated with long-term use of smokeless tobacco, although examples also occur among nonusers.<sup>92,93</sup> This tumor occurs more often in older men, although many examples have also been documented in older women in areas of the country, such as the rural South, where the habit of snuff dipping has been popular among women.<sup>20,93</sup> Verrucous

TABLE 3

TNM Staging of Oral Cancer	
<b>Primary Tumor (T)</b>	
TX	Primary tumor cannot be assessed
T0	No evidence of primary tumor
Tis	Carcinoma in situ
T1	Tumor 2 cm or less in greatest dimension
T2	Tumor more than 2 cm but not more than 4 cm in greatest dimension
T3	Tumor more than 4 cm in greatest dimension
T4	Tumor invades adjacent structures (e.g., through cortical bone, into maxillary sinus, skin, pterygoid muscle, deep muscle of tongue)
<b>Nodal Involvement (N)</b>	
NX	Regional lymph nodes cannot be assessed
N0	No regional lymph node metastasis
N1	Metastasis in a single ipsilateral lymph node, 3 cm or less in greatest dimension
N2	Metastasis in a single ipsilateral lymph node, more than 3 cm but not more than 6 cm in greatest dimension; or in multiple ipsilateral lymph nodes, none more than 6 cm in greatest dimension; or in bilateral or contralateral lymph nodes, none more than 6 cm in greatest dimension
N2a	Metastasis in a single ipsilateral lymph node, more than 3 cm but not more than 6 cm in greatest dimension
N2b	Metastasis in multiple ipsilateral lymph nodes, none more than 6 cm in greatest dimension
N2c	Metastasis in bilateral or contralateral lymph nodes, none more than 6 cm in greatest dimension
N3	Metastasis in a lymph node more than 6 cm in greatest dimension
<b>Distant Metastasis (M)</b>	
MX	Distant metastasis cannot be assessed
M0	No distant metastasis
M1	Distant metastasis
<b>Stage Grouping</b>	
Stage 0	Tis N0 M0
Stage I	T1 N0 M0
Stage II	T2 N0 M0
Stage III	T3 N0 M0; T1 or T2 or T3 N1 M0
Stage IV	Any T4 lesion, or Any N2 or N3 lesions, or Any M1 lesion

Modified from AJCC Manual for Staging of Cancer, 1997, Ed: Fleming ID, et al. Lippincott-Raven Publishers, Philadelphia, PA.

carcinoma most commonly occurs on the buccal mucosa, the mandibular or maxillary vestibule, and the mandibular or maxillary alveolar ridge/gingiva—often corresponding to the site of tobacco placement within the mouth. The tumor presents as a diffuse, thickened plaque or mass with a warty or papillary surface (Figure 20). The lesion is usually white, although some examples with less keratinization may appear pink. In tobacco users, tobacco pouch keratosis may be seen on the adjacent mucosal surfaces; examples in nonusers of tobacco may arise from lesions of so-called proliferative verrucous leukoplakia.<sup>59</sup>

Because verrucous carcinoma is slow growing, exophytic, and well differentiated, it is associated with a much better prognosis than conventional squamous cell carcinoma of the mouth.<sup>20,92</sup> Treatment usually consists of surgical excision without the need for neck dissection because metastasis is rare. However, local recurrences may develop and require re-excision. Also, lesions that arise from proliferative verrucous leukoplakia may recur and undergo dedifferentiation into a more aggressive conventional squamous cell carcinoma.<sup>59</sup>

**METASTASIS**

Metastases from oral squamous cell carcinomas most frequently develop in the ipsilateral cervical lymph nodes. Tumors from the lower lip and floor of mouth may initially involve the submental nodes. Contralateral or bilateral cervical metastases also can occur, especially in tumors of the base of tongue, in advanced tumors, and in tumors that occur near the midline. Involved nodes usually are enlarged, firm, and nontender to palpation. If the tumor has perforated the capsule of the involved node and invaded into the surrounding connective tissue (extracapsular



TABLE 4

Five-year Relative Survival Rates for Oral and Oropharyngeal Cancer (SEER Data, 1992 to 1997) <sup>a</sup>									
Stage	Total	All Races		Total	Whites		African Americans		
		Male	Female		Male	Female	Total	Male	Female
Localized	81.9	81.3	82.9	82.3	82.0	82.8	71.5	65.2	80.6
Regional Spread	46.4	46.0	47.3	48.4	48.5	48.1	28.8	26.0	37.7
Distant Metastasis	21.1	19.8	24.3	21.4	21.8	20.6	17.6	9.9	38.7
All Stages	55.8	53.9	59.8	58.4	57.3	60.6	34.3	28.3	50.5

spread), the node will feel fixed and immovable. As many as 30 percent of oral cancers have cervical metastases, either palpable or occult, at the time of initial evaluation.<sup>94</sup> In particular, the tongue has a rich blood supply and lymphatic drainage, which accounts for the fact that up to 66 percent of patients with primary tongue lesions have neck disease at the time of diagnosis.<sup>95</sup> Distant metastases are most common in the lungs, but any part of the body may be affected.

### Staging

Staging of oral cancer is important for establishing proper treatment and determining prognosis. Tumors are staged using the TNM system, where T represents the size of the primary tumor, N indicates the status of the regional lymph nodes, and M indicates the presence or absence of distant metastases. This system is outlined in Table 3.

Survival of patients with oral and oropharyngeal cancer is strongly related to the stage of disease at diagnosis. According to the 1973-to-1988 SEER data from the National Cancer Institute, the five-year relative survival rate for patients with localized disease is 81.9 percent. However, the survival rate drops to 46.4 percent for patients with regional spread and to 21.1 percent for those with distant metastases (Table 4).<sup>9</sup>

TABLE 5

Components of an Oral Cancer Examination*
<b>1. Extraoral examination</b>
<ul style="list-style-type: none"> <li>• Inspect head and neck.</li> <li>• Bimanually palpate lymph nodes and salivary glands.</li> </ul>
<b>2. Lips</b>
<ul style="list-style-type: none"> <li>• Inspect and palpate outer surfaces of lip and vermillion border.</li> <li>• Inspect and palpate inner labial mucosa.</li> </ul>
<b>3. Buccal mucosa</b>
<ul style="list-style-type: none"> <li>• Inspect and palpate inner cheek lining.</li> </ul>
<b>4. Gingiva/alveolar ridge</b>
<ul style="list-style-type: none"> <li>• Inspect maxillary/mandibular gingiva and alveolar ridges on both the buccal and lingual aspects.</li> </ul>
<b>5. Tongue</b>
<ul style="list-style-type: none"> <li>• Have patient protrude tongue and inspect the dorsal surface.</li> <li>• Have patient lift tongue and inspect the ventral surface.</li> <li>• Grasping tongue with a piece of gauze and pulling it out to each side, inspect the lateral borders of the tongue from its tip back to the lingual tonsil region (Figure 21).</li> <li>• Palpate tongue.</li> </ul>
<b>6. Floor of mouth</b>
<ul style="list-style-type: none"> <li>• Inspect and palpate floor of mouth.</li> </ul>
<b>7. Hard palate</b>
<ul style="list-style-type: none"> <li>• Inspect hard palate.</li> </ul>
<b>8. Soft palate and oropharynx</b>
<ul style="list-style-type: none"> <li>• Gently depressing the patient's tongue with a mouth mirror or tongue blade, inspect the soft palate and oropharynx.</li> </ul>

\*A good oral examination requires an adequate light source, protective gloves, 2x2 gauze squares, and a mouth mirror or tongue blade.

## DIAGNOSIS AND TREATMENT

Because most individuals are seen more commonly by primary care physicians and general dentists than by specialists, it is important for these clinicians to perform screening examinations to identify potential oral and pharyngeal cancers. Table 5 summarizes the recommended components of an oral cancer examination (Figure 21).<sup>90</sup> When a suspicious lesion is identified, a conventional biopsy using a scalpel or small biopsy forceps remains the best and most accurate means of assessing it. As stated by Alexander et al., “Noninvasive screening techniques such as cytologic testing (including brush biopsy)... have many pitfalls and should not be considered as substitutes for biopsy when there is concern about malignancy.”<sup>96</sup> The biopsy can be obtained by the primary caregiver or by referral to a head and neck specialist (e.g., otolaryngologist/head and neck surgeon, oral and maxillofacial surgeon, etc.).

In addition to the need for improved early detection by clinicians, it is also important that the patient and general public are knowledgeable about the disease.<sup>43,97</sup> Delays in identification and recognition of suspicious lesions contribute to advanced stage at diagnosis and lower survival statistics.<sup>98-105</sup>

A complete, detailed discussion about the management of oral cancer and precancerous lesions is beyond the scope of this article. Generally speaking, it has been recommended that leukoplakias that show moderate epithelial dysplasia or worse be removed or destroyed if possible.<sup>2</sup> The management of lesions showing mild dysplasia depends on the size, location, and apparent cause of the lesion. Sometimes early dysplastic lesions may be reversible if the source of irritation (e.g., smoking) can be eliminated. Molecular markers, such as DNA content and loss of heterozygosity, hold the promise of becoming important tools for predicting the risk of malignant transformation for oral leukoplakias.<sup>106-108</sup>

The patient with invasive oral cancer is best managed by a coordinated, multidisciplinary team of health care professionals, which may include a head and neck surgeon, oral and maxillofacial pathologist, general pathologist, radiation oncologist, neuroradiologist, reconstructive surgeon, medical oncologist, general dentist, oral and maxillofacial surgeon, maxillofacial prosthodontist, dental hygienist, nurse specialist, speech pathologist, nutritionist, and tobacco cessation counselor.<sup>109</sup>

Up to 15 percent of individuals with oral cancer have been identified to harbor a second primary cancer; therefore, it is important that a complete head and neck examination, including the larynx, is performed.<sup>110</sup> Many clinicians perform an endoscopic examination to include the larynx, esophagus, trachea, and lungs in order to identify other potential lesions in the high-risk patient. For patients who present with a neck mass but no obvious primary site (or if the neck mass is more amenable to biopsy than the primary tumor), a fine needle aspiration remains the diagnostic method of choice rather than an open biopsy, because open biopsy has been reported to be related to a lower survival rate when not accompanied by a simultaneous neck dissection.<sup>111,112</sup>

Imaging studies are now routinely performed to evaluate the primary tumor and neck disease. Both contrast-enhanced computed tomographic (CT) scans and magnetic resonance imaging (MRI) may be utilized in determining the extent of the primary tumor, invasion, regional lymph node status, and distant metastatic disease, thereby providing important staging information.<sup>113,114</sup> Positron emission tomography (PET) scans are also becoming an increasingly popular tool for the identification of primary, recurrent, and metastatic disease.

Treatment options are variable and depend on the size and location of the primary tumor, lymph node status, presence or absence of distant metastases, the patient's ability to tolerate

treatment, and the patient's desires. Surgery and/or radiation therapy remain the gold standards for treatment of cancers of the lip and oral cavity. Oropharyngeal cancer may be treated with surgery and/or radiation therapy for early-stage disease. For advanced-stage disease, surgery with adjuvant radiation therapy may be indicated, whereas recent evidence suggests that the addition of chemotherapy to radiation therapy may provide a survival advantage over radiation therapy alone in this population.<sup>115,116</sup> It is important to take into account disease status and prevalence of occult disease in the neck when evaluating primary cancers of the lip, oral cavity, and oropharynx.<sup>117</sup> Regardless of the treatment modality used, many patients will require consideration of problems related to airway protection, enteral feedings, xerostomia, mucositis, dysphagia, and voice change.

## CONCLUSIONS

The ability to control oral and oropharyngeal cancer will depend on two cornerstones: prevention and early diagnosis. Continuing educational campaigns are needed on the local, state, and national level in order to educate the public about the risk factors and early signs/symptoms associated with this disease. Individuals also need to be encouraged to seek regular professional oral examinations by a dentist and/or physician. Finally, health care workers must be encouraged to perform oral cancer examinations as part of their patient care regime, and to be knowledgeable about early signs of oral carcinoma.<sup>118,119</sup> CA

## REFERENCES

- American Cancer Society, Cancer facts and figures 2002. Atlanta, GA: American Cancer Society; 2002.
- Neville BW, Damm DD, Allen CM, et al. Oral & maxillofacial pathology. 2nd ed. Phila., PA: Saunders; 2002;337-369.
- Silverman S Jr. Demographics and occurrence of oral and pharyngeal cancers. The outcomes, the trends, the challenge. *J Am Dent Assoc* 2001;132:7S-11S.
- Silverman S Jr. Epidemiology. In: Silverman S Jr ed. *Oral Cancer*. 4th ed. Hamilton, Ontario, Canada: BC Decker Inc; 1998;1-6.
- Chen JK, Katz RV, Krutchkoff DJ. Intraoral squamous cell carcinoma. Epidemiologic patterns in Connecticut from 1935 to 1985. *Cancer* 1990;66:1288-1296.
- Llewellyn CD, Johnson NW, Warnakulasuriya KA. Risk factors for squamous cell carcinoma of the oral cavity in young people—a comprehensive literature review. *Oral Oncol* 2001;37:401-418.
- Schantz SP, Yu GP. Head and neck cancer incidence trends in young Americans, 1973-1997, with a special analysis for tongue cancer. *Arch Otolaryngol Head Neck Surg* 2002;128:268-274.
- Swango PA. Cancers of the oral cavity and pharynx in the United States: An epidemiologic overview. *J Public Health Dent* 1996;56:309-318.
- Ries LAG, Hankey BF, Miller BA, et al. *Cancer Statistics Review 1973-1988*. National Cancer Institute, NIH Publication No. 91-2789, 1991.
- Silverman S Jr, Shillitoe EF. Etiology and Predisposing Factors. In: Silverman S Jr ed. *Oral Cancer*, 4th ed. Hamilton, Ontario, Canada: BC Decker Inc; 1998, 7-24.
- Goldberg HI, Lockwood SA, Wyatt SW, et al. Trends and differentials in mortality from cancers of the oral cavity and pharynx in the United States, 1973-1987. *Cancer* 1994;74:565-572.
- Caplan DJ, Hertz-Picciotto I. Racial differences in survival of oral and pharyngeal cancer patients in North Carolina. *J Public Health Dent* 1998;58:36-43.
- Mashberg A, Boffetta P, Winkelmann R, et al. Tobacco smoking, alcohol drinking, and cancer of the oral cavity and oropharynx among U.S. veterans. *Cancer* 1993;72:1369-1375.
- Jovanovic A, Schulten EA, Kostense PJ, et al. Tobacco and alcohol related to the anatomical site of oral squamous cell carcinoma. *J Oral Pathol Med* 1993;22:459-462.
- Andre K, Schraub S, Mercier M, et al. Role of alcohol and tobacco in the aetiology of head and neck cancer: A case-control study in the Doubs region of France. *Oral Oncol, Eur J Cancer* 1995;31B:301-309.
- Blot WJ, McLaughlin JK, Winn DM, et al. Smoking and drinking in relation to oral and pharyngeal cancer. *Cancer Res* 1988;48:3282-3287.
- Lewin F, Norell SE, Johansson H, et al. Smoking tobacco, oral snuff, and alcohol in the etiology of squamous cell carcinoma of the head and neck. A population-based case-referent study in Sweden. *Cancer* 1998;82:1367-1375.
- Silverman S Jr, Griffith M. Smoking characteristics of patients with oral carcinoma and the risk for second oral primary carcinoma. *J Am Dent Assoc* 1972;85:637-640.
- Zhang ZF, Morgenstern H, Spitz MR, et al. Marijuana use and increased risk of squamous cell carcinoma of the head and neck. *Cancer Epidemiol Biomarkers Prev* 1999;8:1071-1078.
- Brown RL, Suh JM, Scarborough JE, et al. Snuff dippers' intraoral cancer: Clinical characteristics and response to therapy. *Cancer* 1965;18:2-13.
- Winn DM, Blot WJ, Shy CM, et al. Snuff dipping and oral cancer among women in the southern United States. *N Engl J Med* 1981;304:745-749.
- Bouquot JE, Meckstroth RL. Oral cancer in a tobacco-chewing U.S. population – no apparent increased incidence or mortality. *Oral Surg Oral Med Oral Pathol Oral Radiol Endod* 1998;86:697-706.
- Johnson N. Tobacco use and oral cancer: A global perspective. *J Dent Educ* 2001;65:328-339.
- Pindborg JJ, Murti PR, Bhonsle RB, et al. Oral submucous fibrosis as a precancerous condition. *Scand J Dent Res* 1984;92:224-229.
- Murti PR, Bhonsle RB, Pindborg JJ, et al. Malignant transformation rate in oral submucous fibrosis over a 17-year period. *Community Dent*

- Oral Epidemiol 1985;13:340-341.
26. Murti PR, Bhonsle RB, Gupta PC, et al. Etiology of oral submucous fibrosis with special reference to the role of areca nut chewing. *J Oral Pathol Med* 1995;24:145-152.
  27. Miller CS, White DK. Human papillomavirus expression in oral mucosa, premalignant conditions, and squamous cell carcinoma. A retrospective review of the literature. *Oral Surg Oral Med Oral Pathol Oral Radiol Endod* 1996;82:57-68.
  28. Sugarman PB, Shillito EJ. The high risk human papillomaviruses and oral cancer: Evidence for and against a causal relationship. *Oral Dis* 1997;3:130-147.
  29. Lindel K, Beer KT, Laissue J, et al. Human papillomavirus positive squamous cell carcinoma of the oropharynx: A radiosensitive subgroup of head and neck carcinoma. *Cancer* 2001;92:805-813.
  30. Gillison ML, Shah KV. Human papillomavirus-associated head and neck squamous cell carcinoma: Mounting evidence for an etiologic role for human papillomavirus in a subset of head and neck cancers. *Curr Opin Oncol* 2001;13:183-188.
  31. Mork J, Lie AK, Glatte E, et al. Human papillomavirus infection as a risk factor for squamous-cell carcinoma of the head and neck. *N Engl J Med* 2001;344:1125-1131.
  32. Winn DM, Ziegler RG, Pickle LW, et al. Diet in the etiology of oral and pharyngeal cancer among women from the southern United States. *Cancer Res* 1984;44:1216-1222.
  33. Winn DM. Diet and nutrition in the etiology of oral cancer. *Am J Clin Nutr* 1995;61:437S-445S.
  34. Silverman S Jr, Gorsky M, Lozada-Nur F, et al. A prospective study of findings and management in 214 patients with oral lichen planus. *Oral Surg Oral Med Oral Pathol* 1991;72:665-670.
  35. Barnard NA, Scully C, Eveson JW, et al. Oral cancer development in patients with oral lichen planus. *J Oral Pathol Med* 1993;22:421-424.
  36. Eisenberg E. Oral lichen planus: A benign lesion. *J Oral Maxillofac Surg* 2000;58:1278-1285.
  37. Watts JM. The importance of the Plummer-Vinson syndrome in the etiology of carcinoma of the upper gastrointestinal tract. *Postgrad Med J* 1961;37:523-533.
  38. Larsson LG, Sandström A, Westling P. Relationship of Plummer-Vinson disease to cancer of the upper alimentary tract in Sweden. *Cancer Res* 1975;35:3308-3316.
  39. de Visscher JG, Bouwes Bavinck JN, van der Waal I. Squamous cell carcinoma of the lower lip in renal-transplant recipients. Report of six cases. *Int J Oral Maxillofac Surg* 1997;26:120-123.
  40. van Zuuren EJ, de Visscher JGAM, Bouwes Bavinck JN. Carcinoma of the lip in kidney transplant recipients. *J Amer Acad Dermatol* 1988;38:497-499.
  41. Flaitz CM, Nichols CM, Adler-Storzhz K, et al. Intraoral squamous cell carcinoma in human immunodeficiency syndrome virus infection. A clinicopathologic study. *Oral Surg Oral Med Oral Pathol Oral Radiol Endod* 1995;80:55-62.
  42. Flaitz CM, Silverman S Jr. Human Immunodeficiency Virus (HIV)-Associated Malignancies. In Silverman S Jr (ed). *Oral Cancer*, 4th ed. Hamilton, Ontario, Canada: BC Decker, Inc; 1998:165-170.
  43. Yellowitz JA, Goodman HS. Assessing physicians' and dentists' oral cancer knowledge, opinions and practices. *J Am Dent Assoc* 1995;126:53-59.
  44. Arvidson-Bufano UB, Blank LW, Yellowitz JA. Nurses' oral health assessments of nursing home residents pre- and post-training: A pilot study. *Spec Care Dentist* 1996;16:58-64.
  45. Blank LW, Arvidson-Bufano UB, Yellowitz JA. The effect of nurses' background on performance of nursing home resident oral health assessments pre- and post-training. *Spec Care Dentist* 1996;16:65-70.
  46. Yellowitz J, Horowitz AM, Goodman HS, et al. Knowledge, opinions and practices of general dentists regarding oral cancer: A pilot survey. *J Am Dent Assoc* 1998;129:579-583.
  47. Yellowitz JA, Horowitz AM, Drury TF, et al. Survey of U.S. dentists' knowledge and opinions about oral pharyngeal cancer. *J Am Dent Assoc* 2000;131:653-661.
  48. Horowitz AM, Drury TF, Goodman HS, et al. Oral pharyngeal cancer prevention and early detection. Dentists' opinions and practices. *J Am Dent Assoc* 2000;131:453-462.
  49. Horowitz AM, Siriphant P, Sheikh A, et al. Perspectives of Maryland dentists on oral cancer. *J Am Dent Assoc* 2001;131:65-72.
  50. Smith RA, Cokkinides V, von Eschenbach AC, et al. American Cancer Society guidelines for the early detection of cancer. *CA Cancer J Clin* 2002;52:8-22.
  51. United States Preventive Services Task Force (USPSTF). In: *Guide to clinical preventive services: Report of the United States Preventive Services Task Force 2d ed.* Baltimore, MD: Williams & Wilkins, 1996. Available at: <http://www.ahcpr.gov/clinic/cpsix.htm>. Accessed May 17, 2002.
  52. Schwimmer E. Die idiopathischen Schleimhautplaques der Mundhöhle (Leukoplakia buccalis). *Arch Dermat Syph* 1877;9:570-611.
  53. Kramer IR, Lucas RB, Pindborg, JJ, et al. WHO Collaborating Centre for Oral Precancerous Lesions. Definition of leukoplakia and related lesions: An aid to studies on oral precancer. *Oral Surg Oral Med Oral Pathol* 1978;46:518-539.
  54. Shafer WB, Waldron CA. A clinical and histopathologic study of oral leukoplakia. *Surg Gynecol Obstet* 1961;112:411-420.
  55. Axéll T, Pindborg JJ, Smith CJ, et al. Oral white lesions with special reference to precancerous and tobacco-related lesions: Conclusions of an international symposium held in Uppsala, Sweden, May 18-21 1994. International Collaborative Group on Oral White Lesions *J Oral Pathol Med* 1996;25:49-54.
  56. Bouquot JE, Gorlin RJ. Leukoplakia, lichen planus, and other oral keratoses in 23,616 white Americans over the age of 35 years. *Oral Surg Oral Med Oral Pathol* 1986;61:373-381.
  57. Waldron CA, Shafer WG. Leukoplakia revisited: A clinicopathologic study of 3256 oral leukoplakias. *Cancer* 1975;36:1386-1392.
  58. Bouquot JE, Whitaker SB. Oral leukoplakia—Rationale for diagnosis and prognosis of its clinical subtypes or "phases." *Quintessence Int* 1994;25:133-140.
  59. Hansen LS, Olson JA, Silverman S Jr. Proliferative verrucous leukoplakia. A long-term study of thirty patients. *Oral Surg Oral Med Oral Pathol* 1985;60:285-298.
  60. Kahn MA, Dockter ME, Hermann-Petrin JM. Proliferative verrucous leukoplakia. Four cases with flow cytometric analysis. *Oral Surg Oral Med Oral Pathol* 1994;78:469-475.
  61. Zakrzewska JM, Lopes V, Speight P, et al. Proliferative verrucous leukoplakia: A report of ten cases. *Oral Surg Oral Med Oral Pathol Oral Radiol Endod* 1996;82:396-401.
  62. Silverman S Jr, Gorsky M. Proliferative verrucous leukoplakia. A follow-up study of 54 cases. *Oral Surg Oral Med Oral Pathol Oral Radiol Endod* 1997;84:154-157.
  63. Fettig A, Pogrel MA, Silverman S Jr, et al. Proliferative verrucous leukoplakia of the gingiva. *Oral Surg Oral Med Oral Pathol Oral Radiol Endod* 2000;90:723-730.
  64. Damm DD, Curran A, White DK, et al. Leukoplakia of the maxillary vestibule—an association with Viadent? *Oral Surg Oral Med Oral Pathol Oral Radiol Endod* 1999;87:61-66.
  65. Eversole LR, Eversole GM, Kopcik J. Sanguinaria-associated oral leukoplakia: Comparison with other benign and dysplastic leukoplakic lesions. *Oral Surg Oral Med Oral Pathol Oral Radiol Endod* 2000;89:455-464.
  66. Mascarenhas AK, Allen CM, Loudon J. The association between Viadent use and oral leukoplakia. *Epidemiology* 2001;12:741-743.
  67. Pindborg JJ, Renstrup G, Poulsen HE, et al. Studies in oral leukoplakia. V. Clinical and histologic signs of malignancy. *Acta Odont Scand* 1963;21:407-414.
  68. Bánóczy J, Csiba A. Occurrence of epithelial dysplasia in oral leukoplakia. Analysis and follow-up study of 12 cases. *Oral Surg Oral Med Oral Pathol* 1976;42:766-774.
  69. Feller L, Altini M, Slabbert H. Pre-malignant lesions of the oral mucosa in a South African sample: A clinicopathologic study. *J Dent Assoc South Africa* 1991;46:261-265.
  70. Silverman S Jr. Observations on the clinical characteristics and natural history of oral leukoplakia. *J Am Dent Assoc* 1968;76:772-777.
  71. Einhorn J, Wersäll J. Incidence of oral carcinoma in patients with leukoplakia of the oral mucosa. *Cancer* 1967;20:2189-2193.
  72. Bánóczy J. Follow-up studies in oral leukoplakia. *J Maxillofac Surg* 1977;5:69-75.
  73. Pindborg JJ, Jøfist O, Renstrup G, et al. Studies on oral leukoplakia: A preliminary report on the

- period prevalence of malignant transformation in leukoplakia based on a follow-up study of 248 patients. *J Am Dent Assoc* 1968;76:767-771.
74. Kramer IRH. Precancerous conditions of the oral mucosa: A computer-aided study. *Ann R Coll Surg Eng* 1969;45:340-356.
75. Roed-Petersen B. Cancer development in oral leukoplakia: Follow-up of 331 patients. *J Dent Res* 1971;50:711.
76. Silverman S Jr, Gorsky M, Lozada F. Oral leukoplakia and malignant transformation: A follow-up study of 257 patients. *Cancer* 1984;53:563-568.
77. Lind PO. Malignant transformation in oral leukoplakia. *Scand J Dent Res* 1987;95:449-455.
78. Queyrat L. Erythroplasia de gland. *Bull Soc Franc Derm Syph* 1911;22:378-382.
79. Shafer WG, Waldron CA. Erythroplakia of the oral cavity. *Cancer* 1975;36:1021-1028.
80. Mashberg A, Samit A. Early diagnosis of asymptomatic oral and oropharyngeal squamous cancers. *CA Cancer J Clin* 1995;45:328-351.
81. Rossie KM, Guggenheimer J. Thermally induced "nicotine" stomatitis. A case report. *Oral Surg Oral Med Oral Pathol* 1990;70:597-599.
82. Pindborg JJ, Mehta FS, Gupta PC, et al. Reverse smoking in Andhra Pradesh, India: A study of palatal lesions among 10,169 villagers. *Br J Cancer* 1971;25:10-20.
83. Ortiz GM, Pierce AM, Wilson DF. Palatal changes associated with reverse smoking in Filipino women. *Oral Dis* 1996;2:232-237.
84. Smith JF, Mincer HA, Hopkins KP, et al. Snuff-dipper's lesion. A cytological and pathological study in a large population. *Arch Otolaryngol* 1970;92:450-456.
85. Greer RO Jr, Poulson TC. Oral tissue alterations associated with the use of smokeless tobacco by teen-agers. Part I. Clinical findings. *Oral Surg Oral Med Oral Pathol* 1983;56:275-284.
86. Grady D, Greene J, Daniels TE, et al. Oral mucosal lesions found in smokeless tobacco users. *J Am Dent Assoc* 1990;121:117-123.
87. Kaugars GE, Riley WT, Brandt RB, et al. The prevalence of oral lesions in smokeless tobacco users and an evaluation of risk factors. *Cancer* 1992;70:2579-2585.
88. Martin GC, Brown JP, Eifler CW, et al. Oral leukoplakia status six weeks after cessation of smokeless tobacco use. *J Am Dent Assoc* 1999;130:945-954.
89. Silverman S Jr, Dillon WP, Fischbein NJ. *Diagnosis In: Silverman S Jr ed. Oral Cancer*. 4th ed. Hamilton, Ontario, Canada: BC Decker Inc; 1998;41-66.
90. National Institute of Dental and Craniofacial Research. Perform a death-defying act. The 90-second oral cancer examination. *J Am Dent Assoc* 2001;132:36S-40S.
91. Bouquot JE. Oral verrucous carcinoma. Incidence in two US populations. *Oral Surg Oral Med Oral Pathol Radiol Endod* 1998;86:318-324.
92. Ackerman LV. Verrucous carcinoma of the oral cavity. *Surgery* 1948;23:670-678.
93. McCoy JM, Waldron CA. Verrucous carcinoma of the oral cavity. A review of forty-nine cases. *Oral Surg Oral Med Oral Pathol* 1981;52:623-629.
94. Shah JP, Candela FC, Poddar AK. The patterns of cervical lymph node metastasis from squamous carcinoma of the oral cavity. *Cancer* 1990;66:109-113.
95. Ho CM, Lam KH, Wei WI, et al. Occult lymph node metastasis in small oral tongue cancers. *Head Neck* 1992;14:359-363.
96. Alexander RE, Wright JM, Thiebaud S. Evaluating, documenting and following up oral pathological conditions. A suggested protocol. *J Am Dent Assoc* 2001;132:329-335.
97. Centers for Disease Control and Prevention. Preventing and controlling oral and pharyngeal cancer. Recommendations from a national strategic planning conference. *MMWR* 1998;47RR-14.
98. Shafer WG. Initial mismanagement and delay in diagnosis of oral cancer. *J Am Dent Assoc* 1975;90:1262-1264.
99. Elwood JM, Gallagher RP. Factors influencing early diagnosis of cancers of the oral cavity. *Can Med Assoc J* 1985;133:651-656.
100. Guggenheimer J, Verbin RS, Johnson JT, et al. Factors delaying the diagnosis of oral and oropharyngeal carcinomas. *Cancer* 1989;64:932-935.
101. Prout MN, Hereen TC, Barber CE, et al. Use of health services before diagnosis of head and neck cancer among Boston residents. *Am J Prev Med* 1990;6:77-83.
102. Schnetler JF. Oral cancer diagnosis and delays in referral. *Br J Oral Maxillofac Surg* 1992;30:210-213.
103. Smart CR. Screening for cancer of the aerodigestive tract. *Cancer* 1993;72:1061-1065.
104. Carpenter RD, Yellowitz JA, Goodman HS. Oral cancer mortality in Maryland. *Maryland Med J* 1993;42:1105-1109.
105. Hollows P, McAndrew PG, Perini MG. Delays in the referral and treatment of oral squamous cell carcinoma. *Br Dent J* 2000;188:262-265.
106. Rosin MP, Cheng X, Poh C, et al. Use of allelic loss to predict malignant risk for low-grade oral epithelial dysplasia. *Clin Cancer Res* 2000;6:357-362.
107. Sudbø J, Kildal W, Risberg B, et al. DNA content as a prognostic marker in patients with oral leukoplakia. *N Engl J Med* 2001;344:1270-1278.
108. Lippman SM, Hong WK. Molecular markers of the risk of oral cancer. *N Engl J Med* 2001;34:1323-1326.
109. Ord RA, Blanchaert RH Jr. Current management of oral cancer. A multidisciplinary approach. *J Am Dent Assoc* 2001;132:19S-23S.
110. Lippman SM, Hong WK. Second primary tumors in head and neck squamous cell carcinoma: The overshadowing threat for patients with early-stage disease. *Int J Radiat Oncol Biol Phys* 1989;17:691-694.
111. Lefebvre JL, Coche-Dequeant B, Van JT, et al. Cervical lymph nodes from an unknown primary tumor in 190 patients. *Am J Surg* 1990;160:443-446.
112. Kleid S, Millar HS. The case against open neck biopsy. *Aust N Z J Surg* 1993;63:678-681.
113. Som PM, Curtin HD, Mancuso AA. An imaging-based classification for the cervical nodes designed as an adjunct to recent clinically based nodal classifications. *Arch Otolaryngol Head Neck Surg* 1999;125:388-396.
114. Robbins KT. Integrating radiological criteria into the classification of cervical lymph node disease. *Arch Otolaryngol Head Neck Surg* 1999;125:385-387.
115. Forastiere A, Goepfert H, Goffinet D, et al. NCCN practice guidelines for head and neck cancer. National Comprehensive Cancer Network Proceedings. *Oncology* 1998;12:39-247.
116. Calais G, Alfonsi M, Bardet E, et al. Randomized trial of radiation therapy versus concomitant chemotherapy and radiation therapy for advanced-stage oropharynx carcinoma. *J Natl Cancer Inst* 1999;91:2081-2086.
117. Robbins KT, Atkinson JL, Byers RM, et al. The use and misuse of neck dissection for head and neck cancer. *J Am Coll Surg* 2001;193:91-102.
118. Horowitz AM, Goodman HS, Yellowitz JA, et al. The need for health promotion in oral cancer prevention and early detection. *J Public Health Dent* 1996;56:319-330.
119. Goodman HS, Yellowitz JA, Horowitz AM. Oral cancer prevention. The role of family practitioners. *Arch Fam Med* 1995;4:628-636.